

# LIPO-STEM (DUO)<sup>TM</sup>

ADIPOSE TISSUE MSCs PURIFICATION KIT

**ADIPOSE-DERIVED MESENCHYMAL STEM CELLS INJECTIONS IN KNEE, HIP, AND ANKLE OSTEOARTHRITIS: CONSECUTIVE CASE SERIES.**

**Dott. M. Cecchetti, Dott.ssa M. Buoro, Dott. P. Cecconi**



**BPB<sup>TM</sup>**  
m e d i c a

[www.biopsybell.com](http://www.biopsybell.com)



# Introduction

Adipose-derived mesenchymal stem cells (ADMSC) have been thoroughly studied in vitro and in vivo in the last decade, and successfully proven to be a valid therapeutic tool for the conservative treatment of a wide range of diseases (wound healing, vascular diseases, ischemic brain injuries, neurological diseases, osteoarthritis)<sup>(1- 3)</sup>, thanks to their reparative, anti-inflammatory, and angiogenic properties.

Adipose tissue is the ideal donor site: it is an abundant source of mesenchymal stem cells, its harvest is easy, inexpensive, and fast, and can be performed in a single-stage procedure with the following intra-articular injection, and no adverse events have been reported<sup>(4,5)</sup>.

The use of ADMSC is particularly promising in the conservative treatment of early osteoarthritis when replacement surgery can be a premature solution: the microenvironment of the inflamed joints dictates the differentiation of the injected ADMSC into chondrocytes and their secretion of bioactive molecules, having anti-inflammatory, lubricating, angiogenic, antiapoptotic, antifibrotic effects in the receiving site, thus improving symptoms and functional status<sup>(4,6)</sup>.

This has great clinical relevance since osteoarthritis is one of the main causes of disability in the elderly population. Being able to reduce symptoms and slow the progression of this disease can have important social and economic positive drawbacks<sup>(2-3)</sup>.

We present a consecutive case series of 22 patients affected by osteoarthritis, treated with intra-articular injections of ADMSC, obtained using new devices.

# Materials & Methods

From 01/02/19 to 01/02/2022, we proposed this conservative treatment to all patients affected by mild to moderate osteoarthritis, not affected by other major comorbidities (obesity, diabetes, etc.). The only exception was a woman affected by a 3-4 knee osteoarthritis degree, informed preoperatively that the treatment was intended for temporary palliation since prosthetic surgery was indicated. Since the moderate severity of osteoarthritis, arthroplasty was considered an overtreatment and we opted for conservative treatment with intra-articular injection of autologous ADMSC.

We present here a consecutive series of the cases we treated.

In particular:

**21 patients** suffering from arthrosis were treated at "Le Betulle" clinic in Appiano Gentile:

- 18 patients with grade 2-3 gonarthrosis (9 bilateral and 9 unilateral, aged between 53 and 82 years);
- 3 patients with grade 2-3 coxarthrosis, who required ultrasound assistance for targeted intra-articular insertion, aged between 64 and 75 years.

**1 patient** was treated at the "Madonnina" clinic in Milan:

- A 78-year-old female patient with 1-2 grade subastragalic arthrosis, requiring ultrasound-guided injection (See Ch.1)

Chart 1. PATIENTS divided BY INFILTRATION SITE:

Infiltration site	Age	Patients
KNEE	Age 53-63	5 Patients (4 Females + 1 Males)
	Age 64-74	9 Patients (7 Females + 2 Males)
	Age 75-82	4 Patients (3 Females + 1 Male)
HIP	Age 64-75	3 Patients (2 Females + 1 Male)
ANKLE	Age 78	1 Patient (1 Female)

All patients we enrolled underwent preoperative radiographic evaluation with anterior-posterior and lateral projections in the upright position.

All patients were asked to fill in a questionnaire, in which the pre-treatment sensations had to be explained.

- SYMPTOMS: joint crepitation, joint blocks, range of motion (limited or normal)
- RIGIDITY: if present and when more pronounced
- ACHE: frequency, whether while walking, climbing stairs, in bed, sitting, lying down, or bipedal standing.
- DAILY ACTIVITIES: difficulty going down and upstairs, getting on and off the car, getting out of bed, putting on and taking off socks, getting in and out of the bathtub and shower, using the toilet, sitting and getting up from armchairs, carrying out domestic activities.
- SPORT ACTIVITY: pain in running, jumping, squatting, kneeling, twisting.
- LIFE QUALITY: if lifestyles changed, fear of joint failure.

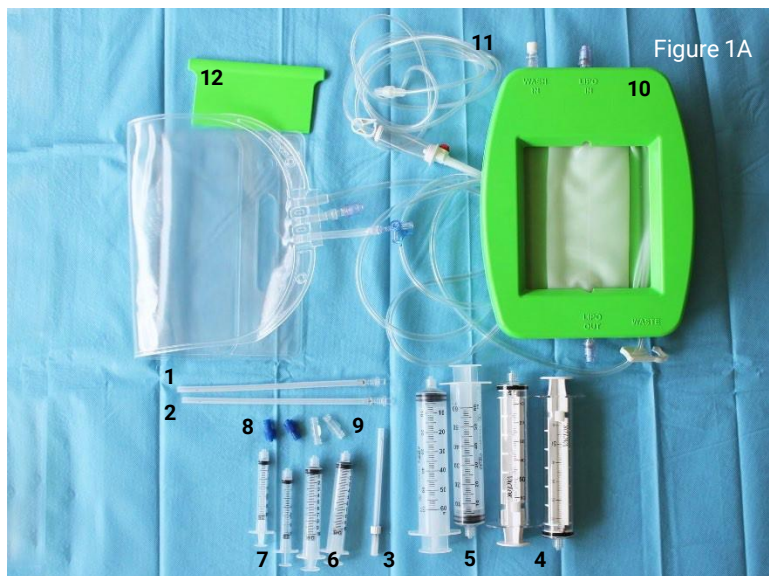
PAIN SCALE: the common **VAS 1-10 scale** was used.

ADMSC were obtained and processed using new devices designed and manufactured by Biopsybell S.r.l., Mirandola (MO, Italy): **LIPO-STEM™** (Fig. 1A) and **LIPO-STEM DUO™** (Fig. 1B).

LIPO-STEM™, the first developed device, is equipped with a filter that washes the harvested adipose tissue with a saline solution while eliminating all the oily and bloody residues which might cause inflammation of the treated tissue. The resulting product is an adipose tissue with a larger structural matrix.

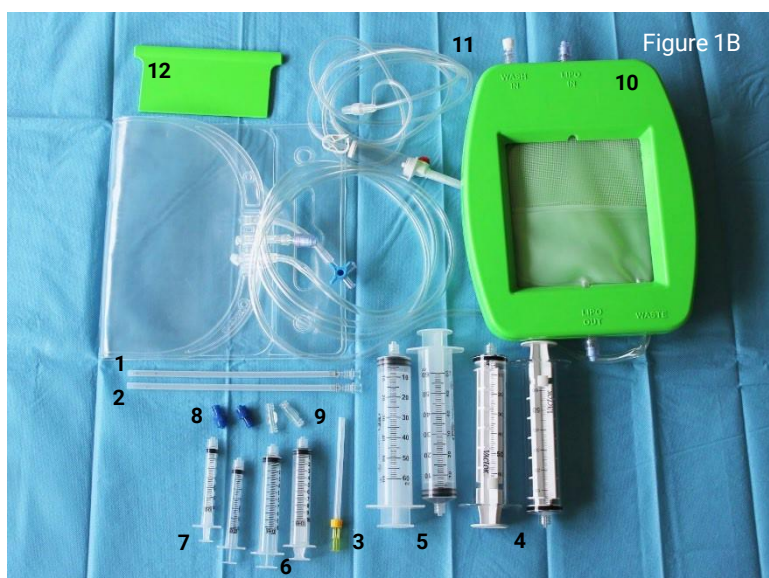
LIPO-STEM DUO™, later developed, is equipped with a further additional filter. Besides washing the harvested tissue, this second filter microfragments it by retaining any fibrotic component of the tissue itself and originating a finer structural matrix.

The finer structural matrix can be injected with smaller needles, thus broadening the possible field of use and making the device more versatile, extending its use for example to small joints.



#### **LIPO-STEM™ Kit composition (Fig. 1A):**

- 1) Nr. 1 cannula 13G with holes
- 2) Nr. 1 cannula 16G with holes
- 3) Nr. 1 infiltration needle 16G x 90 mm
- 4) Nr. 2 60 ml Luer-lock syringes with self-lock for vacuum
- 5) Nr. 2 60ml Luer-lock syringes
- 6) Nr. 2 10ml Luer-lock syringes
- 7) Nr. 2 3ml Luer-lock syringes
- 8) Nr. 2 combi cap FLL / MLL
- 9) Nr. 2 female Luer / female Luer connector
- 10) Nr. 1 filter bag with body and recovery bag
- 11) Nr. 1 infusion line with a closing clamp
- 12) Nr. 1 spatula



#### **LIPO-STEM DUO™ Kit composition (Fig. 1B)**

- 1) Nr. 1 cannula 13G with holes
- 2) Nr. 1 cannula 16G with holes
- 3) Nr. 1 infiltration needle 20G x 90 mm
- 4) Nr. 2 60 ml Luer-lock syringes with self-lock for vacuum
- 5) Nr. 2 60ml Luer-lock syringes
- 6) Nr. 2 10ml Luer-lock syringes
- 7) Nr. 2 3ml Luer-lock syringes
- 8) Nr. 2 combi cap FLL / MLL
- 9) Nr. 2 female Luer / female Luer connector
- 10) Nr. 1 filter bag with body and recovery bag
- 11) Nr. 1 infusion line with a closing clamp
- 12) Nr. 1 spatula



In the operating room, the patients were placed in the supine position and antibiotic prophylaxis was intravenously administered (Ceftriaxone 1g). After scrubbing with an iodopovidone-based solution and draping, the abdomen was chosen as the donor site for the adipose tissue.

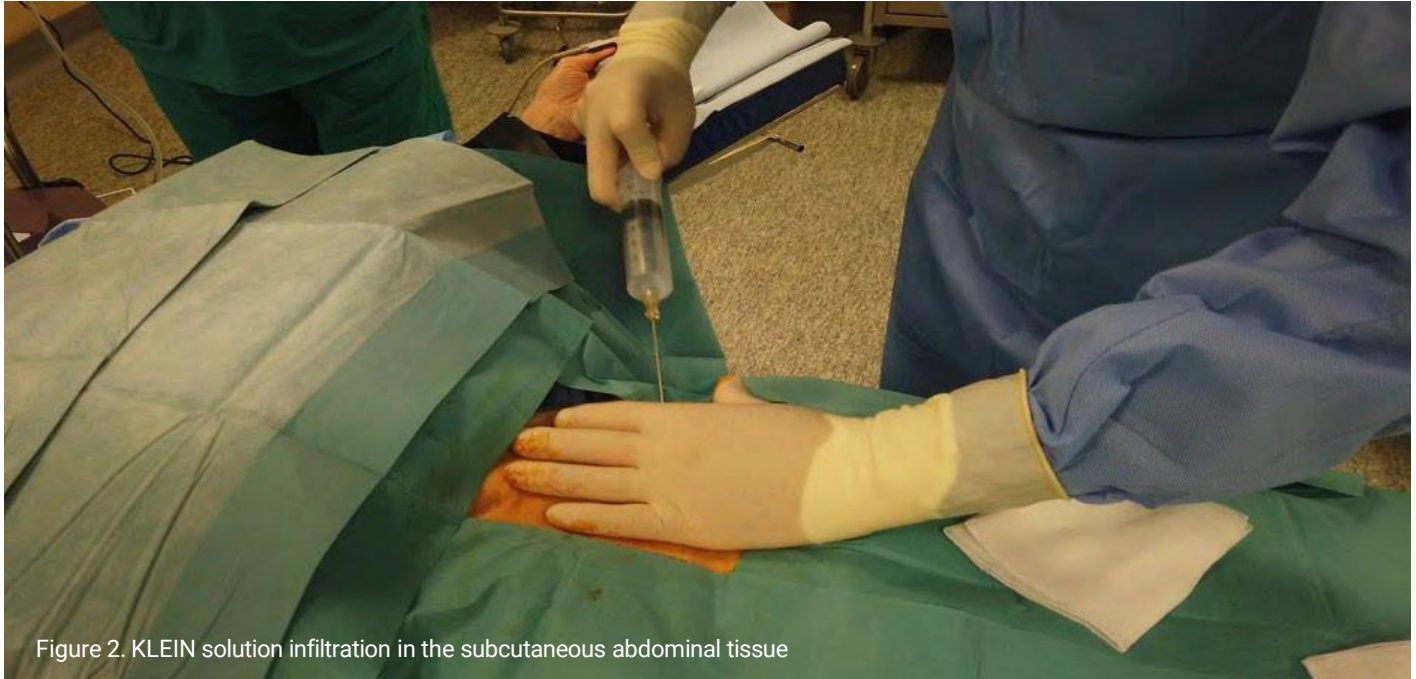
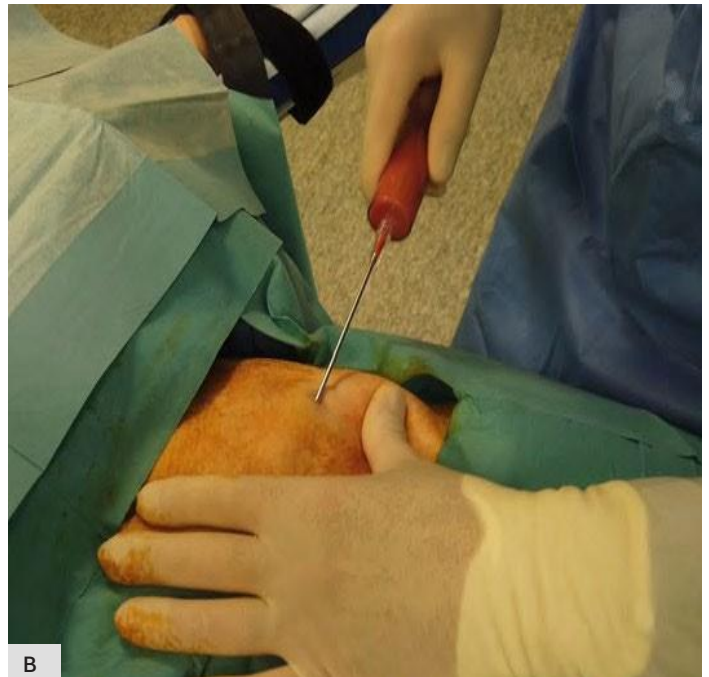
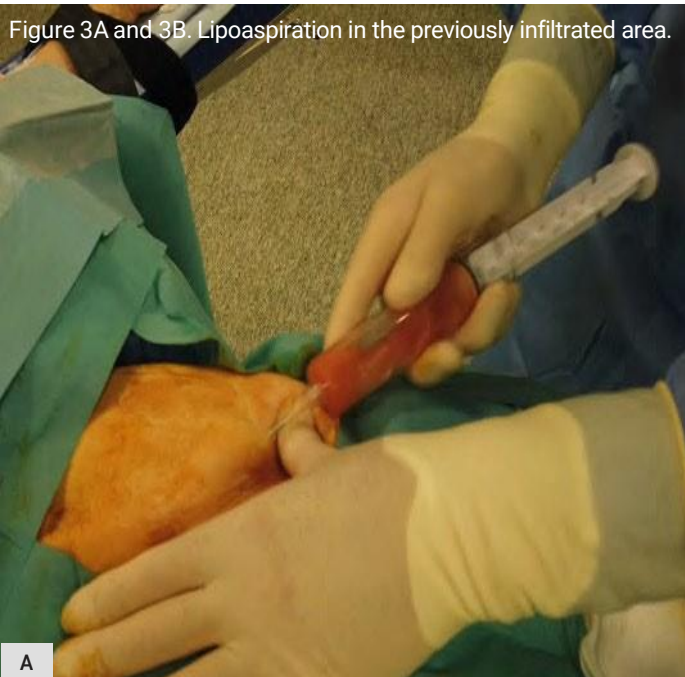Figure 2. KLEIN solution infiltration in the subcutaneous abdominal tissue

Through a 2-3 mm cutaneous incision made under local anaesthesia (1 ml of a 2% Lidocaine), the subcutaneous abdominal tissue was infiltrated with 150 ml of Klein solution (*fig. 2*):

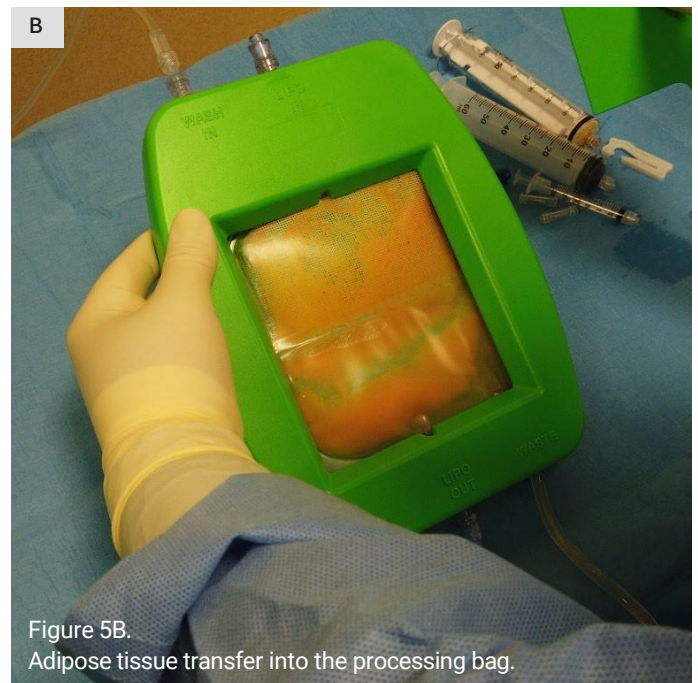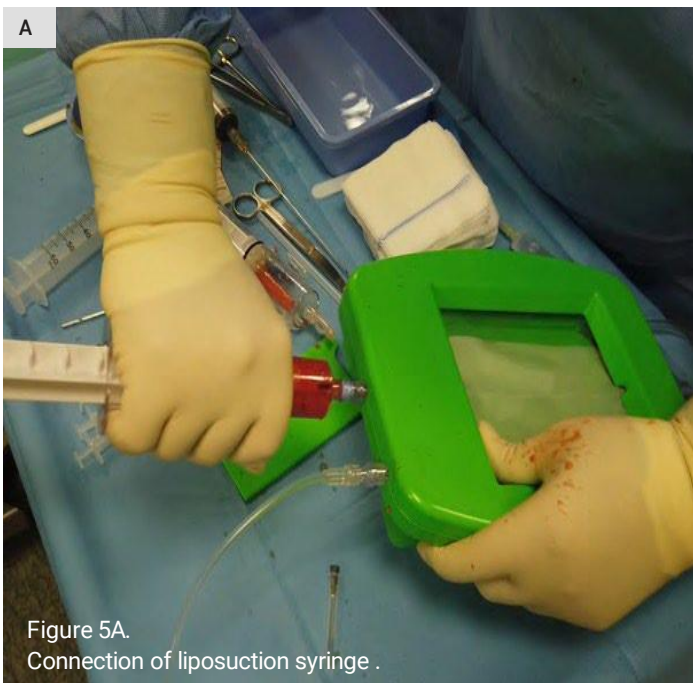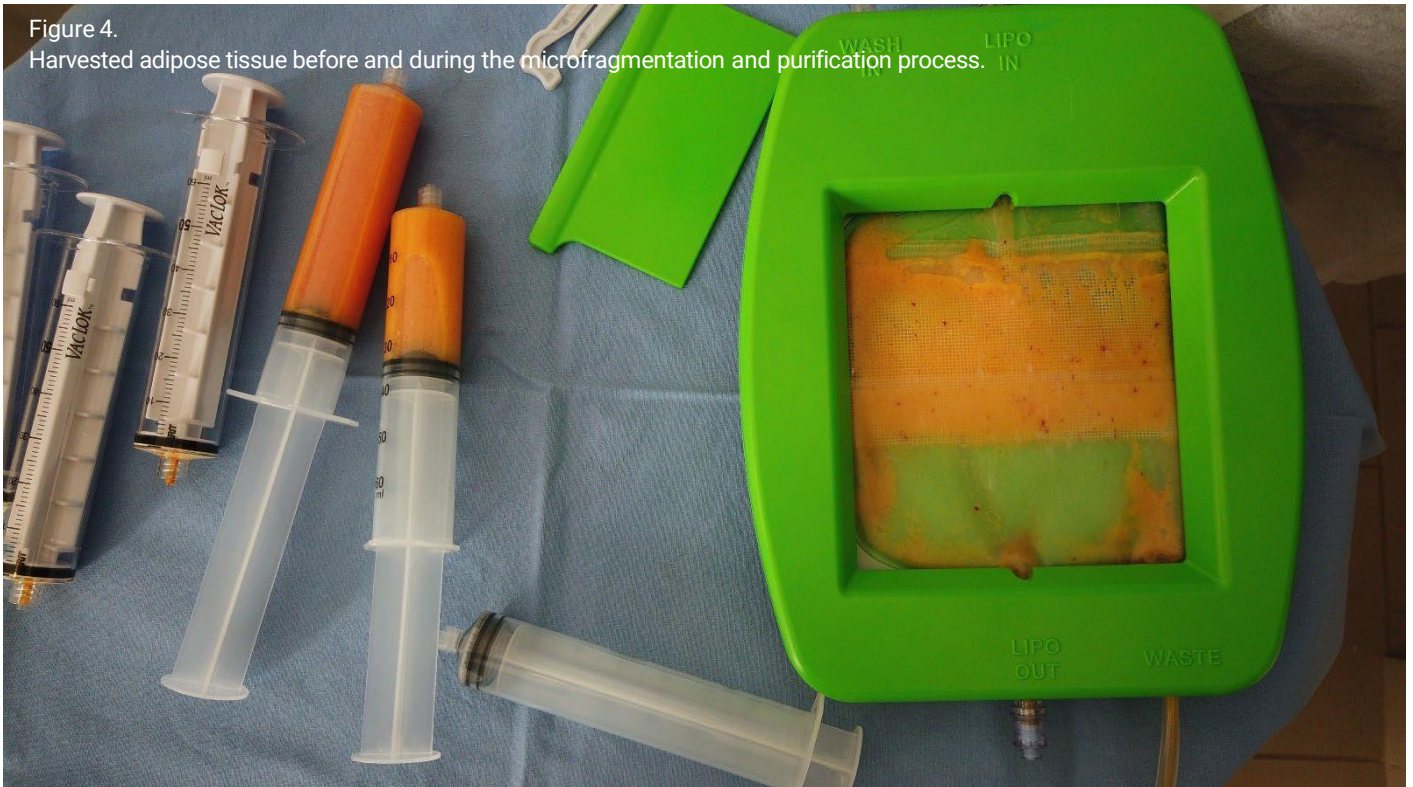- 50 ml of 2% lidocaine
- 1 ml adrenaline
- 10 ml of sodium bicarbonate
- 1000 ml of saline solution

Figure 3A and 3B. Lipoaspiration in the previously infiltrated area.



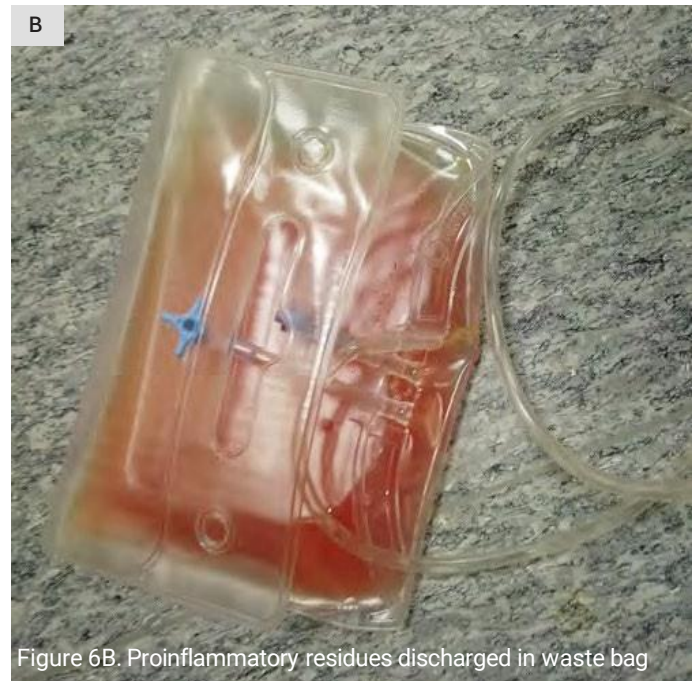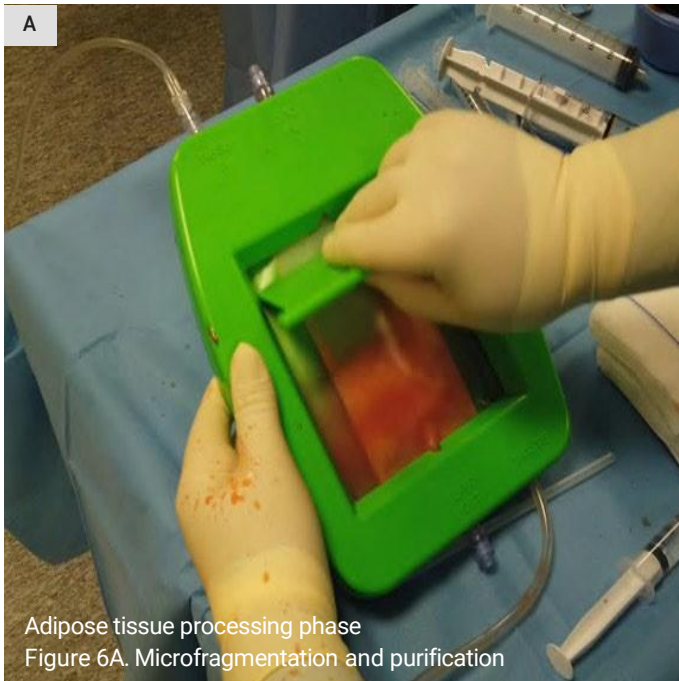


After 7-10 minutes, about 30 ml of adipose tissue were harvested through a wet liposuction technique (*fig. 3A and 3B*). The abdominal incision was closed with a thin bandage, and an adhesive foam pad was applied to the treated area.

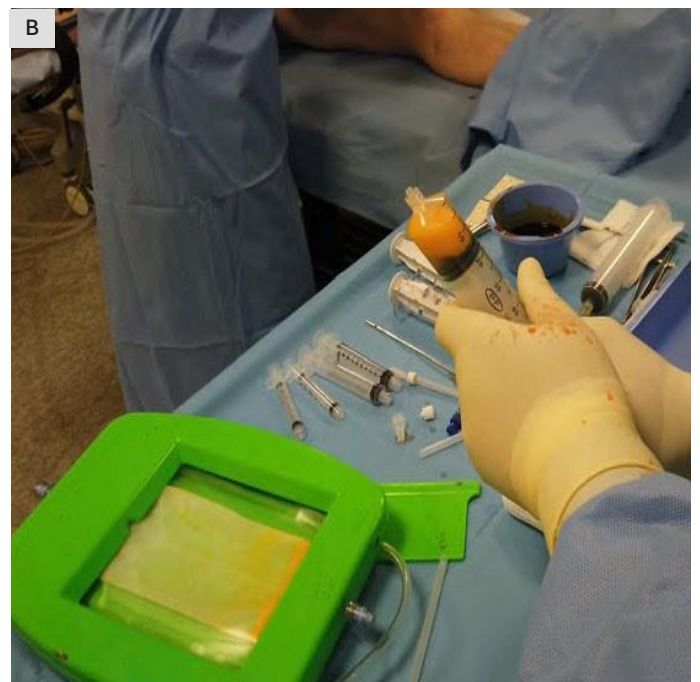


The collected tissue was immediately processed with the LIPO-STEM™ or LIPO-STEM DUO™ device. The liposuction syringe was connected to the device's LIPO-IN valve (*fig. 5A*) and the adipose tissue was transferred to the filter bag (*fig. 5B*).





Following the manufacturer's instruction, the tissue underwent a delicate and fast mechanical processing in a continuous saline solution washing (*fig. 6A*): the clusters of adipose tissue were reduced in size, while the blood components with pro-inflammatory properties and the oily substances were washed away and eliminated through the waste bag connected to the bottom of the filtering box (*fig. 6B*).



In about 5 minutes, we usually obtained 5-10 ml of micro fragmented micronized adipose tissue product (*fig. 7*), which was injected intra-articularly, after cutaneous infiltration with 1 ml of 2% lidocaine (*fig. 8*). The injection point was medicated with a sterile dressing.

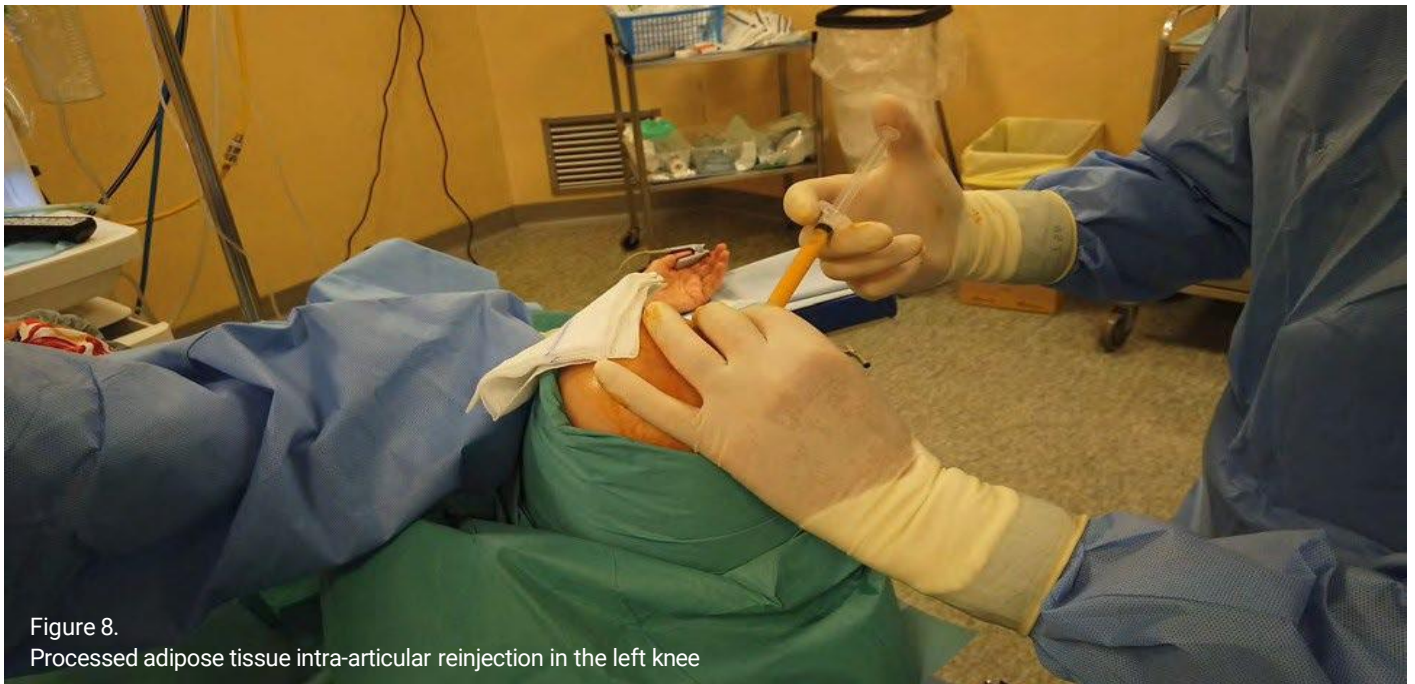

Figure 8.  
Processed adipose tissue intra-articular reinjection in the left knee

In all cases, both the liposuction and the intra-articular injection were performed under local anaesthesia in less than 30 minutes, the patients reported just a little discomfort during the injection, but most of them had an instant articular pain reduction and all of them were able to go home soon after the procedure with no contraindications to weight-bearing.

The same questions of the preoperative questionnaire were asked immediately after surgery and then 3, 6 and 12 months postoperatively, after objective orthopaedic evaluation to detect joint effusion, joint goniometric deficits, and postural passages.

# Results

CHART 2- results divided by infiltration site, age, sex, laterality, single or double filter, and VAS values.

	AGE	Patients	F	M	Treatment	SINGLE FILTER (LIPO- STEM™)	DOUBLE FILTER (LIPO- STEM DUO™)	VAS PRE- operative	VAS POST- operative	VAS 3 Months	VAS 6 Months	VAS 12 Months
KNEE (Gonarthrosis)	53-63	5	1		Bi-		X	4-6	1-2	1-2	1-2	1-2
			1		Bi-		X	4-6	1-2	1-2	1-2	1-2
			1		Bi-		X	4-6	1-2	1-2	1-2	1-2
			1		Mono-	X		4-6	1-2	1-2	1-2	3-4
				1	Bi-	X		5	1	1	1	---
	64-74	9	1		Bi-	X		5-6	1-2	1-2	1-2	3-4
			1		Bi-	X		5-6	1-2	1-2	1-2	3-4
			1		Bi-		X	5-6	1-2	1-2	1-2	1-2
			1		Bi-		X	5-6	1-2	---	---	---
			1		Mono-		X	5-6	1-2	---	---	---
			1		Mono-	X		5-6	1-2	---	---	---
			1		Mono-	X		7	7-8	7-8	7-8	Arthroplasty
				1	Bi-	X		6	1	1	1	3-4
				1	Mono-	X		7	6	6	---	---
	75-82	4	1		Mono-	X		5	1-2	1-2	1-2	3-4
			1		Mono-	X		5	1-2	1-2	1-2	3-4
			1		Mono-	X		Null	Null	Arthroplasty	---	---
				1	Bi-	X		6	1	1	1	3-4
HIP (Coxarthrosis)	64-75	2	1		Mono-	X		6	0-1	0-1	0-1	3-4
				1	Mono-		X	7	6	6	6	Arthroplasty
		1	1		Mono-	X		8	8	Arthroplasty	---	---
ANKLE (Subastragalic arthrosis)	78	1	1		Mono-	X		6	0-1	0-1	0-1	3-4

## GONARTHROSIS

### 53-63 years:

- 1 male patient treated bilaterally with a single filter (LIPO-STEM™), with excellent results on pain and articularity with preoperative VAS 5 and postoperative VAS 1 at 3 and 6 months.
- 4 female patients: 3 bilateral treatments with double filter (LIPO-STEM DUO™) showed good results with preoperative VAS between 4-6 and post-operative VAS between 1-2 at 3-6-12 months. 1 female patient treated monolaterally with a single filter (LIPO-STEM™) (preoperative VAS 4-6) showed improvement especially in the short term (VAS post-operative and 6 months 1-2, VAS at 12 months 3-4).



# Results

## 64-74 years:

- 2 male patients: 1 with bilateral treatment/single-filter with good result with preoperative VAS 6 and postoperative VAS 1, at 3-6 months, VAS 3-4 at 12 months. The other was treated monolaterally with a single filter (LIPO-STEM™) with poor results: preoperative VAS 7 and postoperative VAS 6 at 3 months.
- 7 females: 4 treated bilaterally: 2 with a single filter (LIPO-STEM™) with a good result in the short term (VAS preoperatively 5-6 and 1-2 at 6 months, 3-4 at 12 months), and 2 with double filter (LIPO-STEM DUO™) (VAS preoperatively 5-6 went to 1-2 postoperatively. The result lasted 12 months in one case, the other no longer showed up for controls). 3 treated monolaterally: 1 with double filter (LIPO-STEM DUO™) and good results (VAS preoperatively 5-6 went to 1-2 post-operatory) who no longer showed up after the first check, 1 with poor results (VAS pre-operative 7 and post-operative 7-8 after 6 months who underwent arthroplasty) and 1 treated with a single filter (LIPO-STEM™) with good results (from preoperative VAS 5-6 to post-operative VAS 1-2) who no longer showed up after the first check.

## 75-82 years:

- 1 male treated bilaterally with a single filter (LIPO-STEM™) with excellent results in the short term: preoperative VAS 6 and postoperative VAS 1 at 3-6 months, VAS 3-4 at 12 months.
- 3 female patients treated monolaterally with a single filter (LIPO-STEM™): no results in 1 patient (*fig. 9*) with grade 3rd-4th gonarthrosis, who underwent the placement of a tricompartmental prosthesis 6 months later (the patient had been informed preoperatively that in her case the treatment was essentially palliative since the joint replacement was indicated). 2 female subjects with good preoperative VAS 5 and postoperative VAS 1-2 at 3 and 6 months, but 3-4 at 12 months.

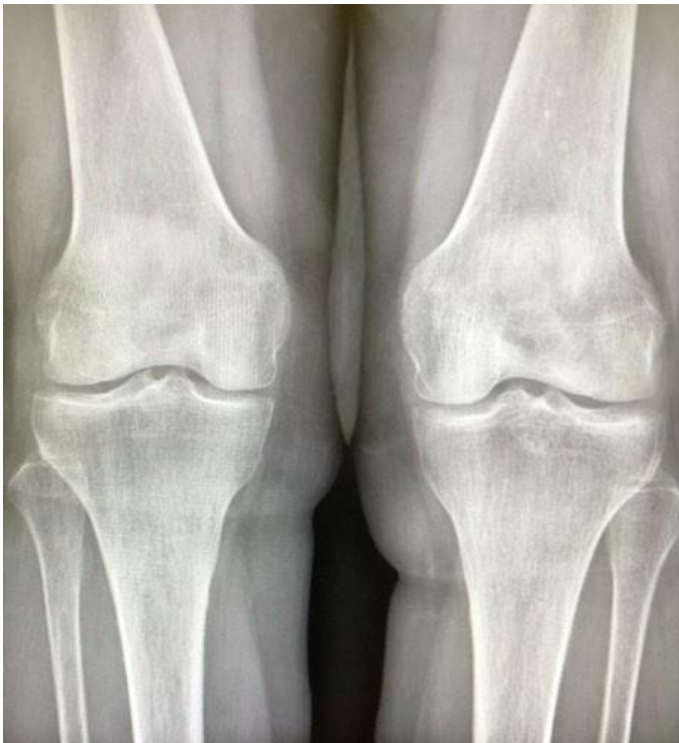

Figure 9.  
Gonarthrosis in an 82 years old woman treated with a single filter



# Results

## COXARTHROSIS

### **64-75 years:**

- 2 females: we had an excellent result in a 64-year-old female with grade 2 coxarthrosis treated with a single filter (LIPO-STEM™), in which pain and joint stiffness had practically disappeared up to 6 months after treatment (preoperative VAS 6, postoperative VAS 0-1) (Fig. 10). A 70-year-old female patient with grade 3 coxarthrosis treated with a single filter (LIPO-STEM™) had no benefit and 3 months after treatment she underwent hip replacement (preoperative VAS 8, postoperative VAS 8)

- 1 male: a 73-year-old patient with grade 2 coxarthrosis treated with a double filter (LIPO-STEM DUO™) showed insignificant improvements 6 months after treatment, with improvement in range of motion but the persistence of pain, for which he underwent arthroplasty soon after (Preoperative VAS 7, postoperative and at 3, 6 months VAS 6).

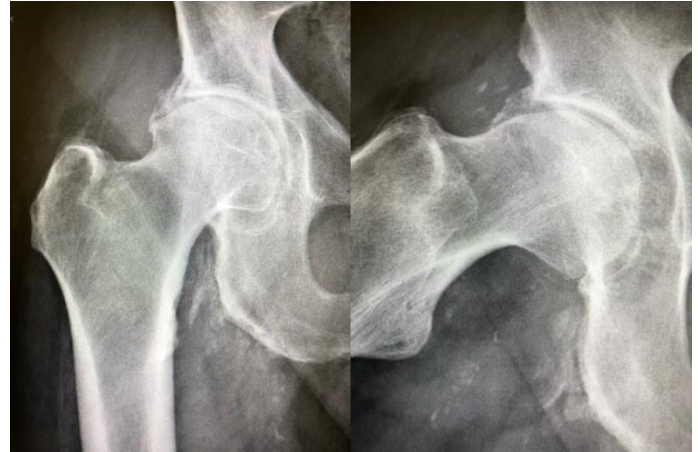

Figure 10.  
Coxarthrosis in a 64-years-old woman treated with

## SUBASTRAGALIC ARTHROSIS

A 78-year-old female patient with grade 1 subastragalic arthrosis, was treated with a single filter (LIPO-STEM™) with excellent results after 6 months: the disappearance of pain and recovery of an excellent range of motion (preoperative VAS 6, postoperative VAS 0-1 up to 6 months, VAS 3-4 at 12 months) (fig 11).

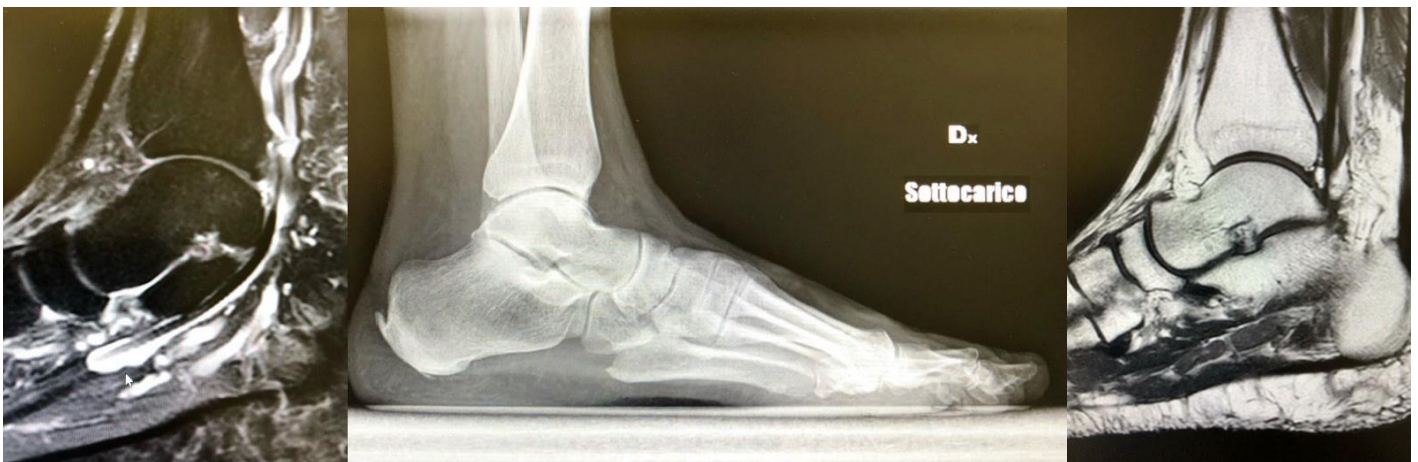


Figure 11.  
Subastragalic arthrosis in a 78-years-old woman treated with single filter.

In all cases, no adverse events were observed, either at the donor or the receiving sites. Most of the patients were generally very satisfied with the significant and prolonged improvement in pain control, functional status and quality of life, with no need for pharmacological therapy up to 6 or even 12 months post-treatment. In some more severe cases, the procedure gave no benefit and the patients underwent prosthetic surgery.

Moreover, LIPO-STEM DUO™ has been shown to trap and remove the fibrous component from the harvested adipose tissue (connective sheaths made up of very thick collagen bundles).

# Discussion

Osteoarthritis, a degenerative disease of synovial joints that causes progressive loss of articular cartilage, is the most common cause of disability in the Western world in older adults, responsible for an increasing number of disabilities and social costs worldwide<sup>(1-3)</sup>.

The knee is the first and most commonly affected joint, followed by the hip<sup>(7)</sup>. When resistant to conservative treatments (NSAIDs, physical therapy), hip osteoarthritis can be treated with hyaluronic intra-articular injections, which however have proven just to slow down the progression of the disease. Total joint replacement is the last resort, but it can be premature in mild to moderate osteoarthritis, also because surgery does not always reduce the pain and is recommended only in severe cases. In the last decade, research has found in adipose-derived mesenchymal stem cells articular injections a promising conservative treatment option, which can not only slow down the progression of cartilage degeneration but also give important lubricating, anti-inflammatory and regenerative support.

Mesenchymal stem cells are multipotent cells with the ability to differentiate into various tissues (bone, tendon, articular cartilage), and have trophic, anti-scarring, immunomodulatory, mitogenic, anti-apoptotic and anti-microbial properties, due to their production of growth factors, bioactive elements and cytokines that detect and signal changes in the microenvironment where they reside<sup>(8)</sup>.

Perivascular cells or pericytes have been reported as the progenitors of mesenchymal stem cells<sup>(9)</sup>. They can be found in the extracellular matrix of various tissues, mainly the bone marrow and, more abundantly, in the adipose tissue. This is an ideal donor tissue because of its easier access, a much-reduced donor site morbidity, and its richness of vascular niches, thus representing an important source of potential healing and regenerative pericytes and ADMSC<sup>(10)</sup>.

Intra-articular injections of autologous fat tissue in patients with osteoarthritis have shown promising results in several studies<sup>(11)</sup>, providing volume, cushioning, support and potential healing and regenerative capabilities<sup>(12)</sup>. A recent systematic review has shown higher clinical and imaging scores in patients treated with ADMSC, with clinical improvement maintained for up to 1 year and evidence of regenerated hyaline cartilage<sup>(14)</sup>. However, studies on ADMSC intra-articular injection are heterogeneous and standardized protocols for tissue collection and processing are lacking<sup>(10)</sup>.

LIPO-STEM™ and its evolution with double filter LIPO-STEM™ DUO are new devices, allowing to process adipose tissue from normal liposuction and obtain a micro-fragmented, micronized product, ready for autologous injection in the affected joints in one operating stage, with no need for laboratory manipulation (enzymatic processing, haemolysis, culturing), thus greatly reducing the preparation time and avoiding higher costs, ethical issues and regulatory constraints. Generally, patients treated with a double filter (LIPO-STEM DUO™) showed better results in the long term, but further evidence should be collected and investigated.

Fat tissue can be easily and rapidly harvested from the abdomen or hip/thigh regions, with minimal donor-site morbidity. While the donor region is being dressed, the lipoaspirate undergoes a rapid, delicate and easy mechanical processing and is reduced in size through a system of filters and a continuous saline solution washing that eliminates blood residues with pro-inflammatory properties, and the final product is ready to be injected immediately.

# Conclusions

The use of LIPO-STEM™ AND LIPO-STEM™ DUO in the consecutive case series we presented here was very handful and safe and allowed us to rapidly obtain a valid product, ready to inject, which led to interesting and encouraging results, with minimal discomfort for the patients and no complications both at the donor and the receiving sites.

The most relevant symptom on which the patients focused when filling the questionnaires pre- and post-operatively, was pain associated with joint stiffness and joint deficit: in most cases these symptoms were greatly relieved, reflecting in a better quality of life. In perspective, this leads to a reduction in social and sanitary costs.

Of course, the cases we collected are few, not allowing us to obtain statistically significant data, but they are part of a larger ongoing study. As we expected, we observed a better response in younger patients and less severe cases of arthritis, but further studies are needed to investigate the importance of other factors (age, gender, lifestyle, ...) that can affect the results, and to understand the real benefit given by ADMSC.

Although literature lacks well-designed and comparative standardized studies, autologous micronized fat injections represent a promising treatment option in osteoarthritis. LIPO-STEM™ and LIPO-STEM DUO™ are effective devices, very easy to use, that gave us promising results in the conservative treatment of mild to moderate osteoarthritis, or in patients not responsive to other conservative treatments, or for palliative treatment in severe cases to delay prosthetic surgery.

## REFERENCES:

1. Bateman M.E., Strong A.L., Gimble J.M., Bunnell B.A. "Concise review: using fat to fight disease: a systematic review of non-homologous adipose-derived stromal/stem cell therapies", *Stem Cells*, 36(9), 1311-1328, 2018.
2. Stonesifer C., Corey S., Ghanekar S., et al. "Stem cell therapy for abrogating stroke-induced neuroinflammation and relevant secondary cell death mechanisms", *Prog Neurobiol*, 158, 94-131, 2017.
3. Filho D.M., Ribeiro P.d.C., Oliveira L.F., et al. "Therapy with mesenchymal stem cells in Parkinson's disease: history and perspectives", *Neurologist* 23(4), 141-147, 2018.
4. Damia E, Chicharro D, Lopez S, et al. Adipose-Derived Mesenchymal Stem Cells: Are They a Good Therapeutic Strategy for Osteoarthritis *Int J Mol Sci*. 2018 Jun 30;19(7).
5. Cattaneo G, De Caro A, Napoli F, Chiapale D, Trada P, Camera A. Micro-fragmented adipose tissue injection associated with arthroscopic procedures in patients with symptomatic knee osteoarthritis. *BMC Musculoskelet Disord*. 2018 May 30;19(1):176.
6. Striano R, Chen H, Bilbool N, et al. Non-Responsive Knee Pain with Osteoarthritis and Concurrent Meniscal Disease Treated With Autologous Micro-Fragmented Adipose Tissue Under Continuous Ultrasound Guidance. *CellR4* 2015; 3 (5): e1690.
7. Dall'Oca C., Breda S., Elena N., et al. "Mesenchymal stem cells injection in hip osteoarthritis: preliminary results", *Acta Biomed* 90(1), 75-80, 2019.
8. Caplan AI, Correa D. The MSC: an injury drugstore. *Cell Stem Cell* 2011; 9: 11-15.
9. Crisan M, Yap S, Casteilla L, Chen C-W, et al. A perivascular origin for mesenchymal stem cells in multiple human organs. *Cell Stem cell* 2008; 3: 301-313.
10. Usulli FG, D'Ambrosi R, Maccario C, et al. Adipose-derived stem cells in orthopaedic pathologies. *Br Med Bull*. 2017 Dec 1;124(1):31- 54.
11. Kolasinski SL, Neogi T, Hochberg MC, et al. 2019 American College of Rheumatology/Arthritis Foundation Guideline for the Management of Osteoarthritis of the Hand, Hip, and Knee. *Arthritis Care Res (Hoboken)*. 2020 Feb;72(2):149-162.
12. Di Marino AM, Caplan AI, Bonfield TL. Mesenchymal stem cells in tissue repair. *Front Immun* 2013;4:201.

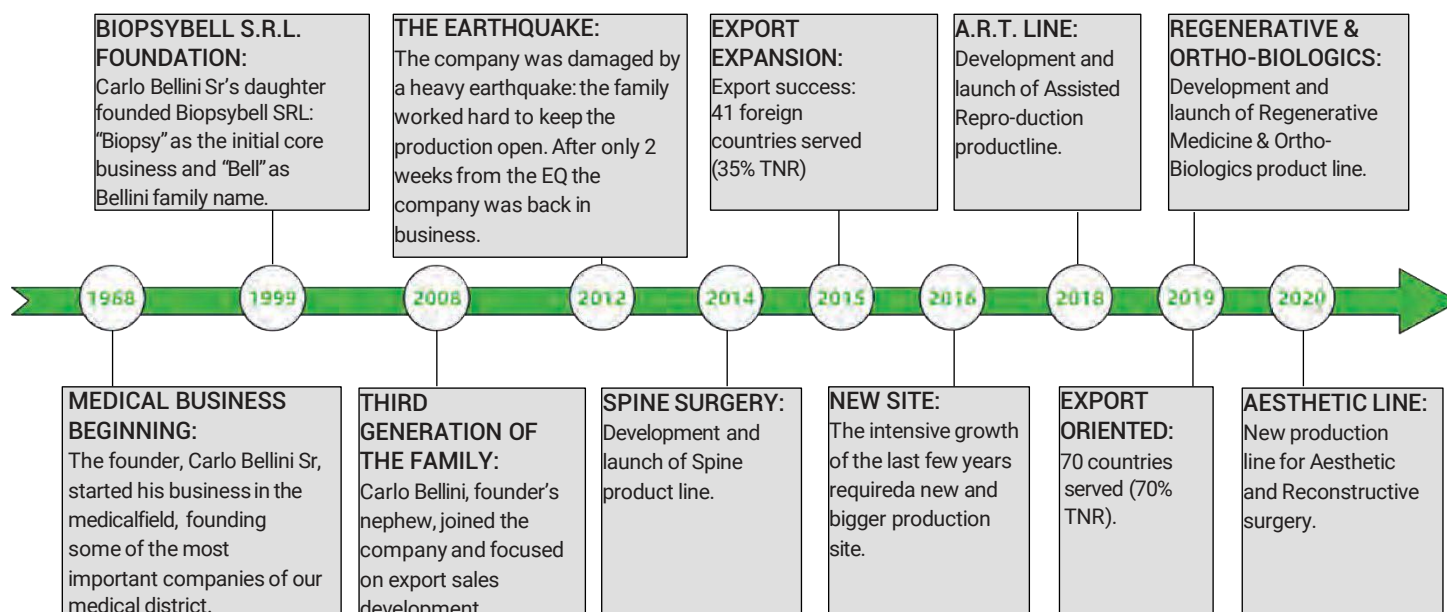


# OUR COMPANY



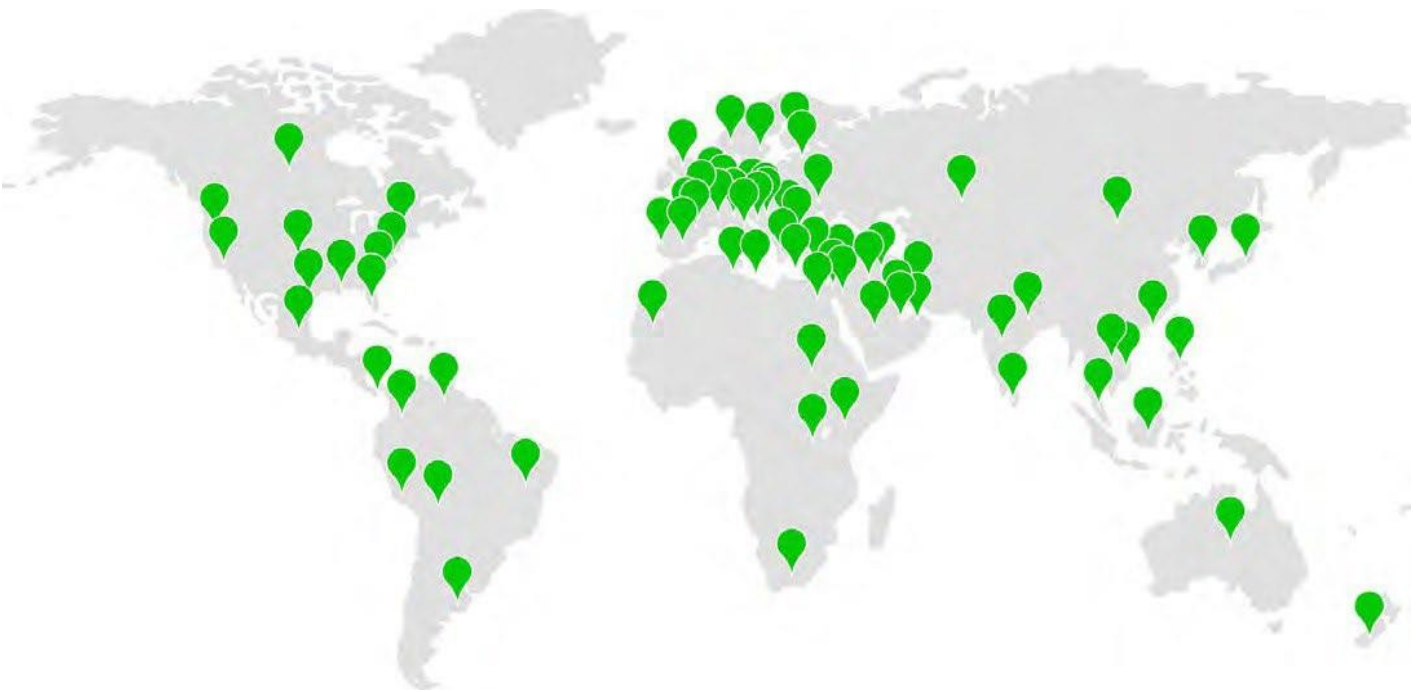**BPB MEDICA™ is an Italian manufacturing company** specialising in the design, production and marketing of high-quality healthcare products for medical use and medical surgery devices.

BPB MEDICA™ was founded in 1999 by the Bellini family, boasting thirty years' experience in the biomedical sector. The founder, Carlo Bellini Sr., started the business in 1968 and has passed down ethics, integrity and spirit of sacrifice to his heirs. Today BPB MEDICA™ has leveraged its 50 years of experience to develop new innovative product lines, growing the company on an international level.





**BPB MEDICA™’s philosophy** is to grow alongside the needs of patients, doctors and hospital staff in general. Backed by the experience acquired by the company’s specialized technical personnel and thanks to newly-adopted technologies, BPB MEDICA™ has quickly managed to make a name for itself in the domestic and international markets.



OUR NUMBERS



EXPERIENCE



COUNTRIES SERVED








CUSTOMERS



PROCEDURES  
performed with our devices

OUR PRODUCT LINES

 <p>SPINE SURGERY</p>	 <p>ORTHO-BIOLOGICS</p>	 <p>ASSISTED REPRODUCTION</p>	 <p>BIOPSY</p>	 <p>INTENSIVE CARE</p>	 <p>AESTHETIC</p>
--	--	--	---	---	--

BPB MEDICA™ provides painstaking service to its clientele and its primary aim is product quality. Our **internal Regulatory and Quality Departments** offer full-service support to our customers in the following activities:

- Quality Systems
- Regulatory Affairs
- Technical documents preparation
- Clinical experimentation
- Vigilance
- Formation
- OEM and Private Label regulatory and quality support

Our **Quality Department** conducts rigorous tests, from the raw materials to the equipment and the finished product. This allowed the company to obtain CE, ISO 13485 and the establishment registration by FDA.

Thanks to the **internal R&D Department** BPB MEDICA™ conducts constant research on the reference pathologies to ever-better qualifying and improving its production standards and aid the development of new products. Functional tests are performed by **R&D Department** in concert with Quality Department to demonstrate the product performance and to make sure that new products maintain their functional characteristics even in the worst case.

BPB MEDICA™ is an established and experienced contract medical equipment manufacturer, with:

- Advanced ISO 8 cleanroom facility for manual & automatic assembly and packaging.
- Metal refinishing department for cutting, grinding, sharpening, cleaning, echogenic marking, sealing, reduction
- Moulding department with vertical and horizontal moulding machines.
- Computerized warehouse with the top-selling items always available in stock and ready to be shipped within 24 hours.



## OUR SERVICES



### QUALITY & REGULATORY DEP.

Our primary aim is product quality and to provide painstaking service. Our regulatory and quality teams conduct rigorous tests for this purpose.



### RESEARCH & DEVELOPMENT

Constant research to increase production and quality standards while developing new products.



### PRODUCTION PROCESS CONTROL

Complete manufacturing process carried out internally, from design to final packaging.



### OEM & PRIVATE LABEL SERVICES

À la carte production, with customer's brand name and custom colour. Full-service support of Regulatory and Quality documentation.



### MARKETING SUPPORT

Video tutorial, case report, presence at the major medical congresses, organization of training and courses.



### FOUR WEEKS DELIVERY


Thanks to the optimization of the production process, we satisfy our customers' orders within 4 weeks.



## CUTTING, GRINDING & ELECTROPOLISHING



## CLEANROOM



## MOULDING DEPARTMENT





Contact us for further information:

**BIOPSYBELL S.R.L. Società Unipersonale**

Via Aldo Manuzio 24

41037 Mirandola – MO – ITALY

T. +39 0535 27850 – F. +39 0535 33526

C.F./P.Iva 02615000367

Società soggetta ad attività di direzione e coordinamento da parte della società Bpunto3 S.r.l.

ADIPOSE-DERIVED MESENCHYMAL STEM CELLS INJECTIONS IN KNEE, HIP AND ANKLE OSTEOARTHRITIS: CONSECUTIVE CASE SERIES.-  
Rev.01 - 24/05/2022



[www.biopsybell.com](http://www.biopsybell.com)

[international1@biopsybell.it](mailto:international1@biopsybell.it)